

# Nonsurgical periodontal treatment

Essayist: Mario Aimetti

## Abstract

The primary goal of nonsurgical periodontal therapy is to control microbial periodontal infection by removing bacterial biofilm, calculus, and toxins from periodontally involved root surfaces. A review of the scientific literature indicates that mechanical nonsurgical periodontal treatment predictably reduces the levels of inflammation and probing pocket depths, increases the clinical attachment level and results in an apical shift of the gingival margin. Another parameter to be considered, in spite of the lack of scientific evidence, is the reduction in the degree of tooth mobility, as clinically experienced.

It is important to point out that nonsurgical periodontal treatment presents limitations such as the long-term maintainability of deep periodontal pockets, the risk of disease recurrence, and the skill of the operator. A high number of post-treatment residual pockets exhibiting bleeding on probing and > 5 mm deep are related to lower clinical stability. The successful treatment of plaque-induced periodontitis will restore periodontal health, but with reduced periodontium. In such cases, anatomical damage from previous periodontal disease will persist and inverse architecture of soft tissue may impair home plaque removal.

The clinician can select one of the following therapeutic options according to the individual patient's needs:

- Quadrant/sextant wise instrumentation (conventional staged debridement, CSD).
- Instrumentation of all pockets within a 24-hour period with (full mouth disinfection [FMD]) or without (full mouth scaling and root planing [FMSRP]) local antiseptics. Both procedures can be associated with systemic antimicrobials.
- CSD or FMD in combination with laser or photodynamic therapy.

Patients with aggressive periodontitis constitute a challenge to the clinician. To date there are no established protocols for controlling the disease. However, data from the literature on the application of the FMD protocol combined with amoxicillin-metronidazole systemic administration are promising.

A new classification in supra- and sub-crestal nonsurgical periodontal therapy will be proposed. The supracrestal therapy includes the treatment of gingivitis, nonsurgical coverage of recession-type defects, treatment of suprabony defects and papilla reconstruction techniques. Within subcrestal periodontal therapy, it is of paramount importance to preserve both marginal tissues and connective fibers inserted in the root cementum at the apical part of the bony defects.

## Nonsurgical periodontal therapy: what does it mean?

Development of a properly sequenced treatment plan is a derivative of the periodontal assessment and diagnosis. Periodontal therapy is diagnosis-driven and should address all local and host factors that impact on the development and progression of periodontal diseases.<sup>1</sup> In addition, it must take in account the expectations and the socioeconomic status of the patients and the final endpoints of the operative protocol.

Periodontal diseases are plaque-induced inflammatory conditions affecting the periodontium, and if left untreated, they may lead to destruction of the tooth-supporting apparatus and eventually to tooth loss.<sup>2</sup> Periodontal breakdown is the results of a complex interplay of bacterial aggression and host response modified by hereditary, systemic and environmental factors such as diabetes mellitus, connective tissue and hematologic disorders, and smoking habits.<sup>3-5</sup> Some of these factors can be modified to reduce patient's susceptibility to periodontitis, but not all. Thus, the reduction/elimination of periodontal pathogens is still the primary goal of the periodontal therapy. The pathogens are organized in biofilm attached to the root surface in a protected environment, which prevents the access of the host immune response, but also of the antimicrobial agents.<sup>6,7</sup> Only therapies achieving the mechanical disruption of the subgingival biofilm have shown to be effective and, hence, periodontal health can be maintained only provided there is adequate plaque control by the patient and

individualized professional subgingival instrumentation.<sup>8</sup>

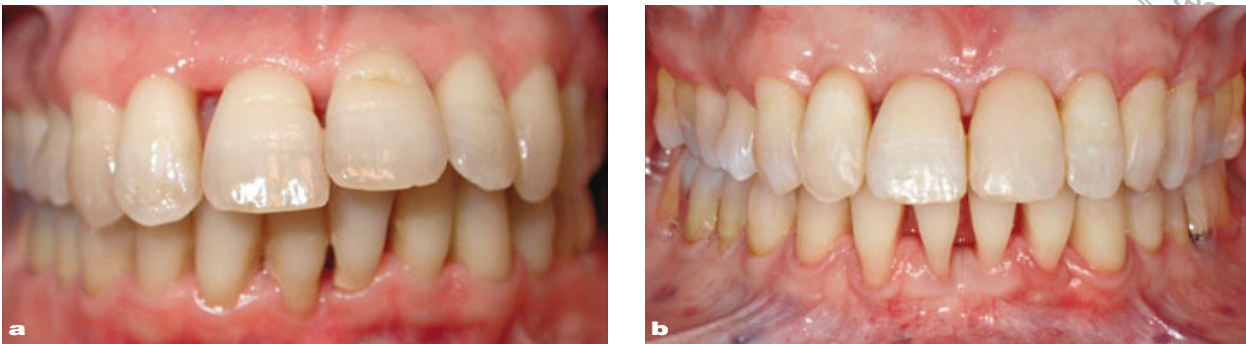In the treatment of aggressive periodontitis, the association of the mechanical instrumentation with systemic antibiotics would seem more effective from a clinical and microbiological point of view.<sup>9</sup>

## Objectives and limitation of nonsurgical periodontal therapy

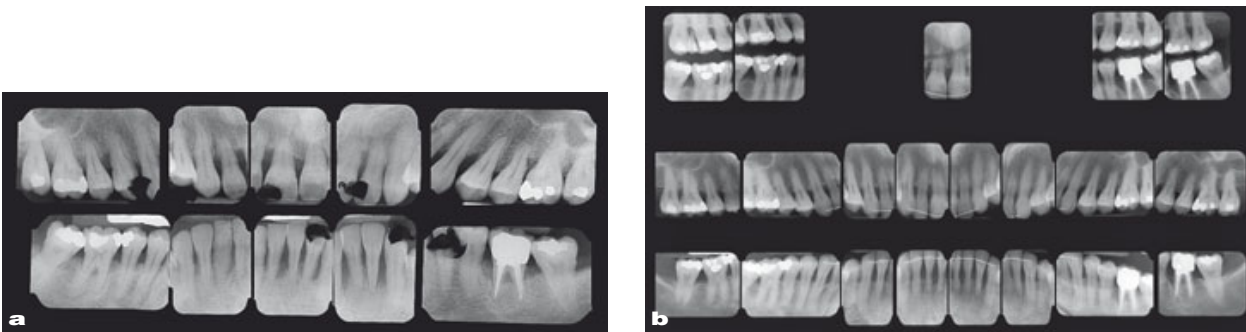
Regardless of the diagnosis of gingivitis, chronic or aggressive periodontitis the nonsurgical periodontal treatment is the cornerstone of the periodontal therapy. It is aimed at removal of supra- and subgingival plaque and calculus deposits and, together with proper supragingival oral hygiene practices, at control of microbial infection and recovery of periodontal health.<sup>10</sup>

Proper supragingival plaque control can effectively reduce gingivitis and it is critical to achieve long-term control of periodontitis.<sup>11,12</sup> Oral hygiene instructions should be given to all patients undergoing periodontal therapy. In our opinion, patients are more motivated to accept treatment recommendations when they are given the opportunity to see infection in their own mouths and they understand the value of treating periodontal disease in relation to their overall health. The clinician must individualize the message to different patients and instruct them in the use of tooth-brushing methods and oral hygiene devices more suitable for their gingival features.<sup>13</sup>

Subgingival instrumentation comprises scaling and root planing by manual



**Fig 1** (a) Baseline clinical image (frontal view) revealing heavy plaque and calculus accumulation, gingival inflammation and severe teeth migration in the second sextant. (b) Twelve years later the complete recovery of the gingival health as well as the spontaneous dental repositioning were achieved by nonsurgical periodontal therapy, occlusal adjustment and supportive therapy with recalls every 4 months. The anterior teeth were stabilized by means of extracoronary splintings. (Courtesy Dr Mariani.)



**Fig 2** Radiographic images of the clinical case presented in Fig 1 at baseline (a) and 12 years later (b). A complete recovery of the periodontal health was evident together with the appearance of the lamina dura. The correct relocation of the anterior teeth in the alveolar process was accompanied by the coronal migration of the alveolar bone crest.

and ultrasonic devices. Tooth scaling is a key component in treating gingivitis, while scaling combined with root planing (SRP) is the gold standard for the non-surgical management of periodontitis.<sup>14</sup> The objective is to provide a root surface compatible with periodontal health by removing adherent and unattached bacterial plaque, microbial toxins, deposits of calculus and contaminated cementum. Due to its strict adherence to the root cementum it is impossible to remove effectively subgingival calculus without removing the underlying cemen-

tum. When patient enters the maintenance therapy the SRP can be replaced by the periodontal debridement in which the removal of root cementum is no longer necessary.

Narrative and systematic reviews have documented the efficacy of SRP in the treatment of periodontitis.<sup>15-18</sup> It results in reductions in bleeding on probing (BoP), probing depth (PD), subgingival bacterial loads and gains in clinical attachment level (CAL). Another parameter to be considered, in spite of the lack of scientific evidence, is the reduction in

the degree of tooth mobility, as clinically experienced.

Nonsurgical periodontal treatment can also lead to spontaneous repositioning of pathologically migrated teeth (Figs 1 and 2) and to closure of diastemas.<sup>19</sup> Control of infection and inflammation, elimination of abnormal occlusal forces and reorientation of supracrestal collagen fibers play an important role in the repositioning of teeth.<sup>20</sup>


The reduction in PD following mechanical instrumentation results from both the shrinkage of the pocket soft tissue wall, manifested as recession of the gingival margin, and the gain in clinical attachment.<sup>21</sup> The magnitude depends on the initial PD. A review by Cobb reported a mean PD reduction and CAL gain of 1.29 mm and 0.55 mm, respectively, for initial PDs of 4 to 6 mm and of 2.16 mm and 1.19 mm, respectively, for pockets initially  $\geq 7$  mm deep.<sup>22</sup> In general, clinicians should evaluate post-SRP healing at 4 to 6 weeks following treatment. After 6 weeks, most of the healing has taken place but soft tissues maturation may continue for an additional 9 to 12 months or longer.<sup>23</sup>

The limitations of SRP are well recognized. The efficacy of the SRP seems to be directly related to the professional skill and the anatomical features but not to the modality of debridement as ultrasonic devices have achieved similar results than hand instrumentation.<sup>24,25</sup> The results are dependent on local factors, such as deep and tortuous pockets and furcations, as well as on patient's factors such as smoking habits, uncontrolled diabetes mellitus and poor self-performed plaque control which may limit the clinical outcomes.<sup>26-29</sup>

Clinical studies reported that subgingival instrumentation failed to eliminate calculus in 10% of periodontal pockets with a depth of  $< 5$  mm, in 23% of pockets with a depth of 5 to 6 mm and in 35% of pockets  $> 6$  mm deep, in 10% of single-rooted teeth and in 30% of multi-rooted teeth.<sup>30,31</sup> (Fig 3) Recently, the improvements in ultrasonic devices, mainly with the modifications of the working tips, have increased the effectiveness of ultrasonic scalers to reach deeper into periodontal pockets or furcation areas.<sup>32</sup> Some studies suggest less cementum removal and less operative discomfort compared to manual SRP but these findings are not universally demonstrated.<sup>33</sup>

It is our opinion that a combined instrumentation approach is indicated to optimize the treatment outcomes and the choice of the treatment modality should be based on the periodontal anatomic features and the individual patients' needs.

When analyzing the SRP outcomes it is important to take in account the long-term maintainability of deep periodontal pockets, and the risk of disease recurrence. Post-treatment residual pockets exhibiting BoP and more than 5 mm deep are related to lower clinical stability with an odds ratio more than 10 for disease progression.<sup>34</sup> Besides anatomical damage from previous periodontal disease will persist and inverse architecture of soft tissue may impair home plaque removal. The choice between non-surgical therapy alone and combined non-surgical and surgical therapy has to take in account the medical history, expectations, psychological profile and degree of compliance (full mouth plaque score [FMPS]  $< 20\%$ ) of the patient, and the fi-



**Fig 3** Electron scanning microscopic images of microbial plaque on the root surface of a hopeless tooth extracted at the completion of hand and ultrasonic instrumentation at magnifications of **(a)**  $\times 48$ , **(b)**  $\times 155$ , and **(c)**  $\times 1,600$ . (Courtesy Dr Scipioni.)

nal purpose of the treatment. If a patient requires a prosthetic rehabilitation it is necessary to surgically correct the anatomical defects caused by the disease and to achieve postoperative PDs less than 4 mm and absence of BoP to optimize the long-term prognosis.

In an attempt to improve subgingival instrumentation new treatment protocols, the adjunctive use of systemic antimicrobials, and new technologies have been suggested.

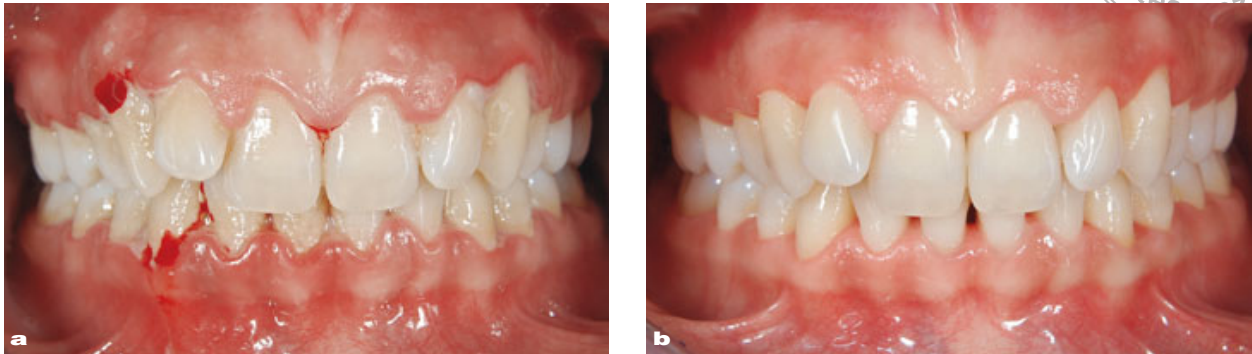## Advances in non-surgical treatment protocols

Traditionally, SRP was carried out either quadrant- or sextant-wise in sessions usually scheduled at weekly intervals (conventional staged debridement [CSD]).<sup>35</sup> Over the last 10 years, many clinical trials have been carried out in an effort to assess whether it would be advantageous to change the standard 4- to 6-week period of nonsurgical periodontal treatment to a full-mouth 24-hour approach. The rationale for the latter strategy was to prevent reinfection

by periodontal pathogens of the already treated periodontal sites from the remaining untreated pockets and from intraoral bacterial reservoirs, such as tongue, tonsils, and other mucous membranes, that could lead to a disease recurrence.<sup>36,37</sup>

Based on these premises the Leuven research group proposed the one-stage full-mouth disinfection protocol (OSFMD) which consisted of full-mouth SRP combined with a disinfection of all intraoral niches by means of the topical application of chlorhexidine, within 24 hours (usually in 2 sessions on 2 consecutive days).<sup>38</sup> They reported clinical and microbiological advantages compared to the CSD therapy in chronic and aggressive periodontitis patients.<sup>39-41</sup>

Other researchers proposed the treatment protocol of the full-mouth SRP (FM-SRP). The supra- and subgingival instrumentation was completed in 24 hours or less with no adjunctive use of antiseptics agents.<sup>42</sup> When the FMSRP was compared to the standard approach neither clinical nor microbiological differences were detected.<sup>43,44</sup>



**Fig 4** Clinical images of ulcero-necrotic gingivitis treated by the administration of antimicrobials and antiseptics, and then by the ultrasonic instrumentation **(a)**. Care was taken not to damage the marginal periodontal tissues. In spite of the destructive features of the pathology, this procedure and the thick gingival biotype made it possible to limit the soft tissues contraction and to preserve the interdental papillary height in the second sextant **(b)**. (Courtesy Dr. Mariani.)

Recently, the full-mouth therapeutic concept has been analyzed in two systematic reviews.<sup>45,46</sup> They concluded that in patients with chronic periodontitis the full-mouth approach achieved more favorable outcomes in terms of PD reduction and CAL gain in deep pocket sites compared to the CSD treatment. However, differences were of small magnitude and clinically not significant. Therefore, the selection of one treatment modality over the other should be account for professional skill, patient preferences and cost-effectiveness.

It is important to point out that full mouth instrumentation is completed in two visits, and thus, the therapist has fewer opportunities to deliver, check, and reinforce oral hygiene instructions. Considering that periodontitis patients should be monitored closely and frequently by the therapist to optimize home plaque control, a strict program of recall appointment has to be scheduled after the full-mouth therapy.<sup>47</sup> The

effective self-performed supragingival plaque control is critical to achieve short- and long-term control of inflammatory periodontal disease.<sup>48</sup>

The full-mouth approach may be indicated for patients with severe and generalized aggressive periodontitis.<sup>47</sup> Despite standard-wise therapy, some aggressive periodontitis patients may experience ongoing periodontal attachment loss probably due both to the persistence of pathogenic bacteria in periodontal soft tissues and the recontamination by pathogens residing in extra-dental reservoirs. Key pathogens such as *Aggregatibacter actinomycetemcomitans*, *Tannerella forsythia*, *Treponema denticola*, *Prevotella intermedia* and *Porphyromonas gingivalis* were found to colonize nearly all the above-mentioned intra-oral niches.<sup>49</sup> In such patients the reduction of the microbial load in few hours may increase the likelihood of long-term improvement in the periodontal condition.

## Supra and subcrestal nonsurgical periodontal treatment

Nowadays, the final goals of the therapy, even in terms of esthetics, play a pivotal role on how we perform non-surgical periodontal instrumentation. For this reason, a new classification in supra- and subcrestal non-surgical periodontal therapy has been proposed.

The supracrestal periodontal therapy includes the treatment of gingivitis, the non-surgical coverage of recession-type defects, the recapture of the interdental papillae and the treatment of suprabony defects. The subcrestal periodontal therapy includes the non-surgical treatment of intrabony defects.

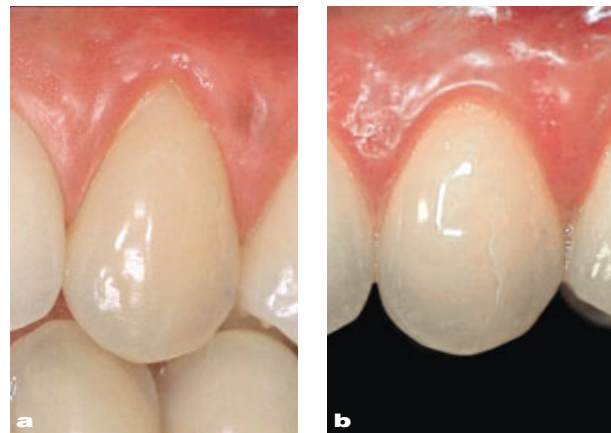
Patients with a diagnosis of gingivitis or exhibiting pseudo pockets due to gingival enlargement have to be treated by gentle supra and subgingival scaling in the respect of soft tissues (Fig 4).<sup>50</sup>

Shallow gingival recessions can be successfully treated by means of SRP and polishing of the exposed root surfaces. It has been demonstrated that the removal of microbial toxins by polishing prevents further progression of gingival recessions. The reduction of root convexity by SRP promotes the coronal shift of the gingival margin.<sup>51</sup> The coronal displacement of gingival margin may result from a mechanism similar to the creeping attachment observed after mucogingival surgery.<sup>52</sup> (Fig 5)

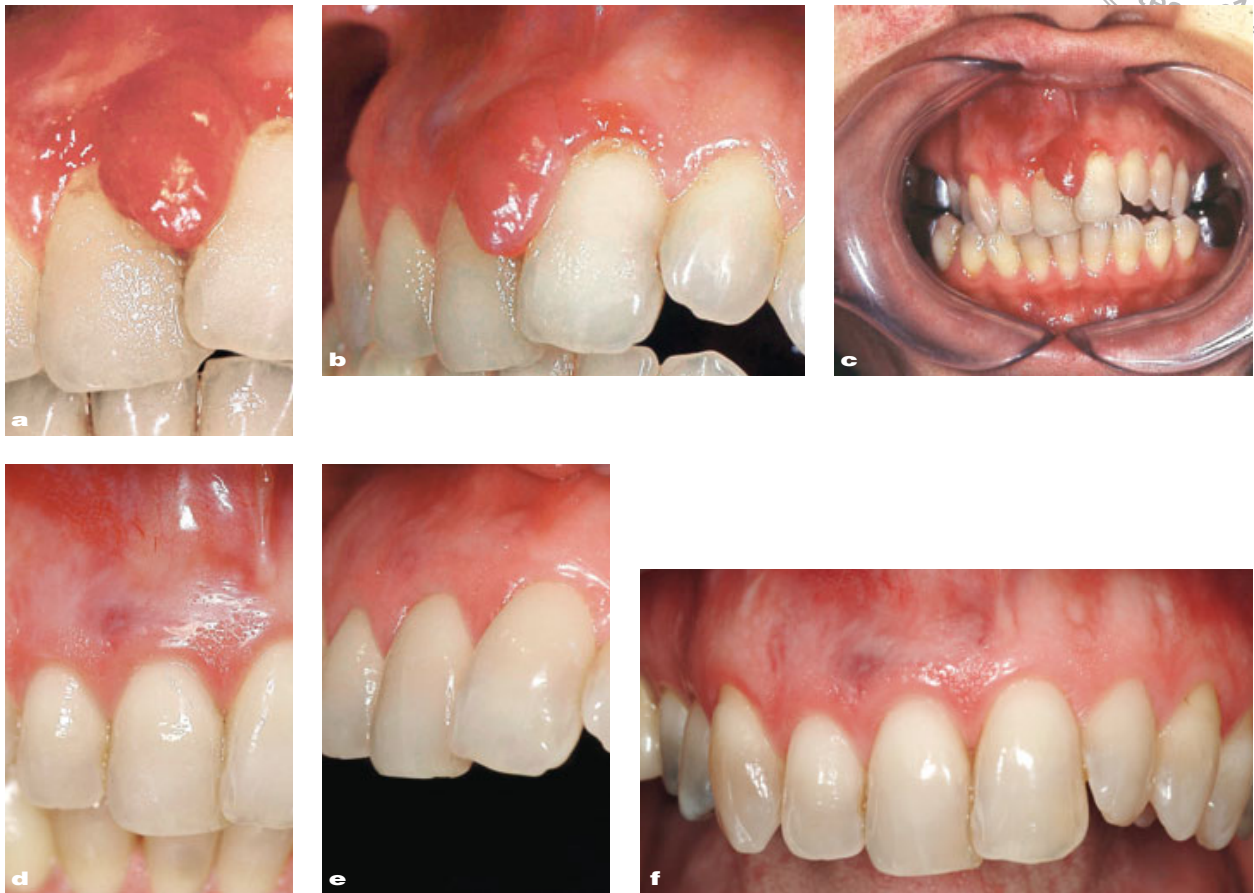In presence of anatomical favorable conditions, the light scarification of the interdental gingival tissues, according to the technique proposed by Shapiro et al,<sup>53</sup> combined with an adequate home and professional plaque control may

lead to the recovery of the interdental papillae. This may be attributed to the increased vascularization and cellular proliferation in the connective gingival tissue due to the “aseptic inflammation” process.

The suprabony pockets are classified in pseudo pockets and suprabony defects. The pseudo pockets are due to anatomical conditions, as altered passive eruption, drugs assumption, as calcium antagonists and cyclosporine A, or gingival neoformations. In such cases the nonsurgical treatment often results in the resolution of the gingival overgrowth and in the recovery of the physiological position of the gingival margin related to the cement-enamel junction (Fig 6).



**Fig 5** Miller's Class I recession type defect located at tooth 1.3 treated by root planing and polishing **(a)**. The coronal displacement of the gingival margin and the almost complete root coverage were achieved by both the detoxification and the gentle reduction of the root convexity **(b)**.



**Fig 6** Angiomatous neof ormation between the upper central incisors in frontal **(a)**, lateral **(b)** and overall frontal **(c)** view. The neof ormation even involved the fornix and the skin surface on the maxillozygomatic area. The patient underwent two surgical sessions to remove the neof ormation. Due to the relapse of the lesion she was advised to extract the upper incisors. The histological analysis of a tissue specimen excised during the nonsurgical instrumentation confirmed the diagnosis of lobular capillary hemangioma of the interdental papilla. One year later, following the nonsurgical periodontal treatment and frequent sessions of motivation and instructions in proper home plaque control measures, the complete recovery of the gingival architecture was achieved without loss of interdental soft tissue **(d and e)**. Frontal view 17 years later **(f)**.

The treatment of suprabony defects differs according to the defect location. In the esthetic area the clinician must carry out a subgingival instrumentation in the respect of marginal soft tissues. It is obvious that the gingival biotype plays a pivotal role and that a progressive apical shift of the gingival margin is expected to happen over time. In the posterior areas greater soft tissue shrinkage is

advocated in order to further decrease the PD.<sup>17</sup>

When SRP is performed in intraosseous defects the therapist must keep in mind the need for a subsequent surgical approach. If the treatment plan involves regenerative surgical procedures it is of paramount importance to preserve the volume of marginal and interdental tissues allowing for flap designs which



guarantee optimal defect coverage at wound closure.<sup>54</sup> If the osseous resective surgery is scheduled it is important to preserve the connective fibers inserted in the root cementum at the apical part of the bony defects.<sup>55</sup> Thus, in the clinical setting the choice of both the instruments and the techniques depends on the final goal of the global treatment planning.

## Systemic antimicrobial therapy

The recognition that specific bacteria are the causative agents of periodontal diseases makes the prospect of targeted antibiotic therapy an attractive goal. Systemic antimicrobial therapy aims at reducing or eradicating specific periodontal pathogens that are not reached by subgingival mechanical instrumentation. The two major periodontopathic bacteria *Aggregatibacter actinomycetemcomitans* and *Porphyromonas gingivalis* may invade gingival epithelial cells and connective tissue, but both microbial species can be suppressed by the administration of antimicrobials.<sup>56,57</sup>

The adjunctive benefits of the systemic antibacterial therapy in the treatment of periodontitis have been reported in systematic reviews presented at North American and European Workshops.<sup>58-60</sup>

It is important to point out that none of the commercially available pharmacologic agents is effective as a monotherapy to treat periodontal diseases. There is scientific evidence that the intake of antimicrobials has to be combined with both proper self-performed supragin-

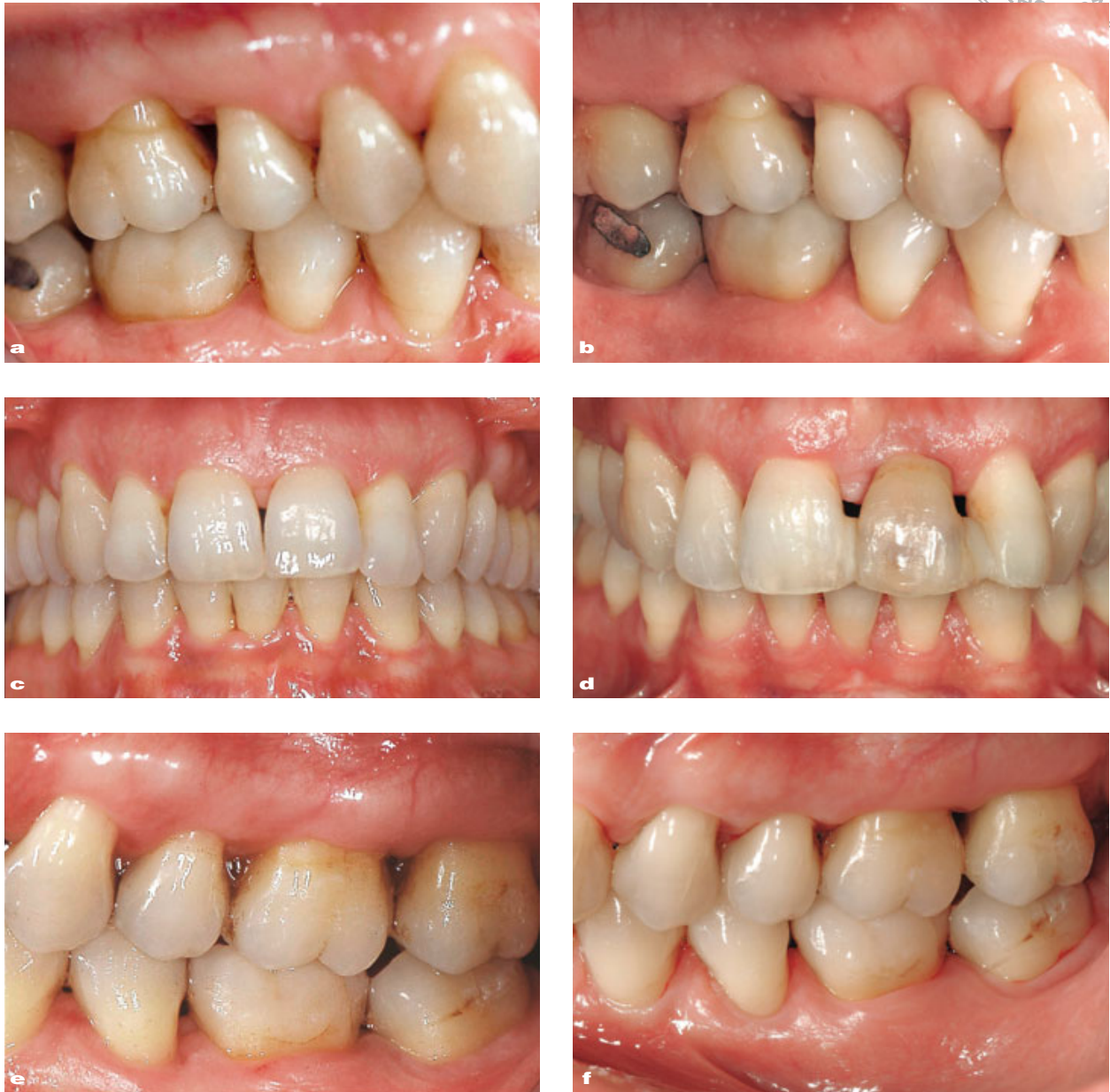gival plaque control and professional removal of subgingival biofilm.<sup>61</sup> The antimicrobial concentration in the periodontal tissues and in the crevicular fluid may be inadequate for the desired antibacterial effects without mechanical disruption of the dental plaque.<sup>62,63</sup>

With regards to the timing of drug administration, the antimicrobials agents would seem to be more effective if administered when the biofilm has been disrupted but has still not reorganized. Thus, mechanical instrumentation should be performed in the shortest time span and the antibiotic intake should start on the day of SRP completion so as to achieve effective antimicrobial concentration in the gingival crevicular fluid.<sup>58-60</sup>

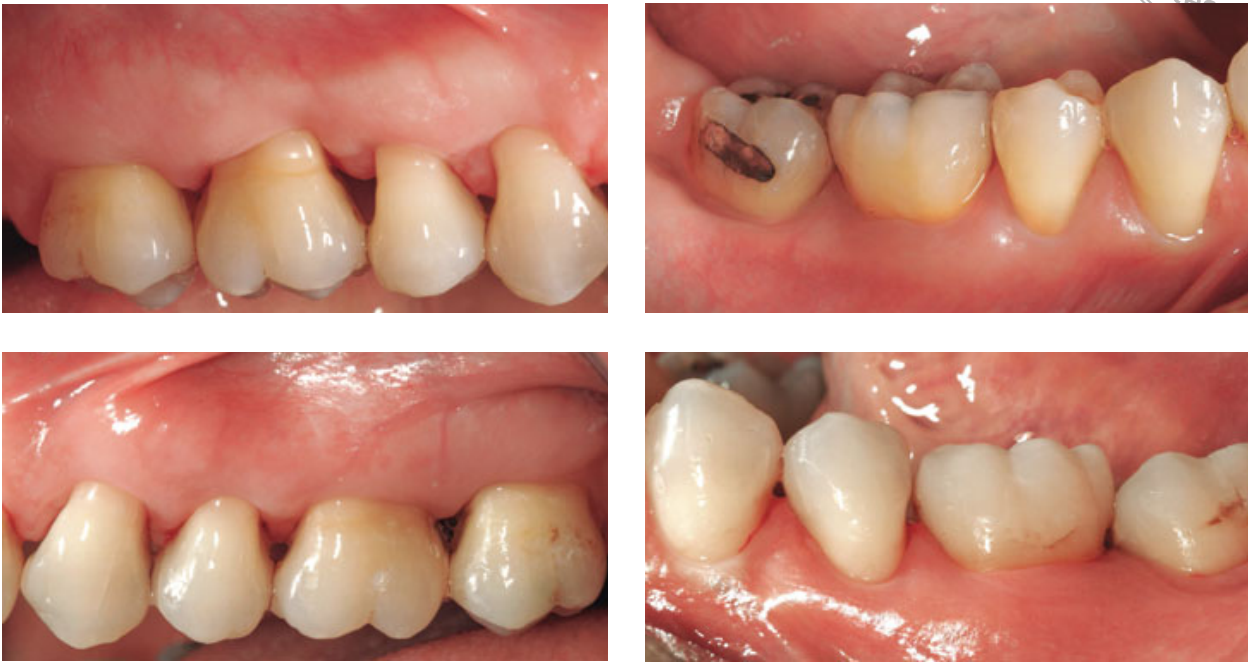Adjunctive antimicrobial therapy with systemic antibiotics kills bacteria out of the range of root surface instrumentation and affects periodontal pathogens in other areas of the oral cavity. This additional effect will reduce bacterial counts on the tongue and other mucosal surfaces, thus potentially delaying in recolonization of subgingival sites by the pathogenic bacteria. The added clinical benefits of systemic antimicrobial combined with SRP over SRP alone have been observed in deep pocket sites and ranged between 0.2 and 0.6 mm for CAL gain and between 0.2 and 0.8 mm for PD reduction.<sup>60</sup>

Metronidazole, tetracycline and the combination of metronidazole and amoxicillin achieved the best results, but there is not enough evidence to support a drug regimen, including appropriate dosage and duration.<sup>59</sup>

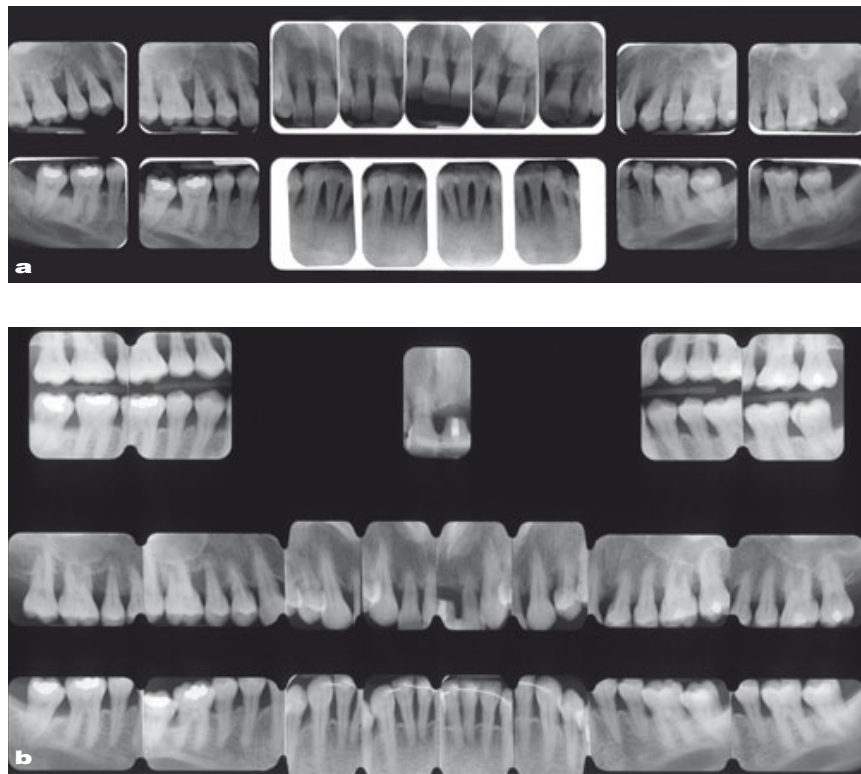
The disadvantages related to drugs intake include uncertain patient compli-



**Fig 7** 28-year-old Caucasian woman presented with the chief complaint of difficulties in speech and mastication due to advanced mobility of several teeth. Good general health, amount of microbial plaque inconsistent with the severity of periodontal tissue destruction, familiar aggregation supported the diagnosis of generalized aggressive periodontitis. Clinical images at baseline **(a, c, e)** and 16 years later **(b, d, f)**. The patient underwent the OSFMD in accordance to the protocol by Quirynen et al<sup>38</sup> in association with systemic antibiotic intake. The supportive periodontal therapy was performed every 3 months. The patient displayed a good compliance with a plaque index score < 10% and an optimal tissues response **(b, d, f)**. The left upper central incisor was extracted during the etiological therapy and the crown was splinted to the neighboring teeth as provisional treatment. The patient refused the implant rehabilitation and the whitening treatment. At present the splinting is still in place.



**Fig 8** Buccal view of the first, third, fourth and the sixth sextants. You can observe the optimal patient' self-performed oral hygiene, the healthy condition of the marginal periodontal tissues and the partial recapture of the interdental papillary tissue.



**Fig 9** Radiological images of the case in Fig 7 at baseline **(a)** and 16 years later **(b)**. We can observe the radiological appearance of the lamina dura and the remineralization of the supportive bone.

ance, increased risk of adverse drug reactions such as toxicity and hypersensitivity, the potential for the selection of multiple antibiotic-resistant organisms, and the overgrowth of opportunistic pathogens.<sup>64</sup>

The emergence of antibiotics resistance is a result of their indiscriminate use. Dentists can play a central role in halting antimicrobials resistance by restricting their prescription to certain patients and periodontal conditions. The administration of antimicrobials may be of clinical relevance in patients with aggressive periodontitis or severe and progressing forms of periodontitis.<sup>58-60</sup>

Patients with aggressive periodontitis constitute a challenge to the clinician. The severity of the disease has been attributed both to the high susceptibility of the host and to the virulence of the subgingival microbiota. To date there are no established protocols for controlling the disease. However, data from the literature on the application of the FMD protocol combined with amoxicillin-metronidazole systemic administration are promising (Figs 7 to 9). In patients with adequate home plaque control (FMPS < 15%) and good compliance to a strict maintenance therapy the combined treatment resulted in additional 0.7 mm in mean PD reduction and 1.00 in clinical attachment gain in deep pocket sites. In addition, *A. actinomycetemcomitans* was eliminated from 53% of the treated subjects at 6 months after therapy.<sup>9</sup>

The systemic amoxicillin plus metronidazole would also seem to enhance the effects of full-mouth SRP in moderate-to-advanced periodontitis patients. Sites on molars benefited significantly more than non-molar sites.<sup>65</sup>

## New technologies

Microscopy, lasers, photodynamic therapy and air-polishing instruments may aid in the antimicrobial treatment of periodontal diseases.

Effective periodontal treatment presupposes a reliable identification of calculus. Tactile perception has traditionally been used for calculus detection but it failed to identify all subgingival accretions.<sup>66</sup> The use of an operative microscope may improve both calculus detection and elimination. In addition, the ability to visually debride the root surfaces may improve the chances of success in a more conservative and minimally invasive way.

Lasers are the most promising new type of devices in non-surgical management of periodontitis. In spite of the high variety of lasers, a limited number has been employed in dentistry. Periodontal lasers include diode lasers, Er:YAG (erbium doped: yttrium, aluminium, and garnet) and Nd:YAG (neodymium doped: yttrium, aluminium, and garnet) lasers and CO<sub>2</sub> lasers.<sup>67</sup> The application of a dental laser in the treatment of chronic periodontitis is based on the purported benefits of subgingival curettage, significant decreases in subgingival pathogenic bacteria, and hemostasis.<sup>68,69</sup> However, when used directly to root surface for calculus removal it can cause excessive heat and results in root damage.<sup>70</sup> The Er:YAG laser technology has shown higher clinical applicability for its efficacy in removing subgingival plaque and calculus without significantly damaging the root surface.<sup>71</sup>

Despite the large number of publications there is still controversy among

clinicians regarding the use of laser-mediated therapy in the treatment of chronic periodontitis. There is limited evidence suggesting that lasers achieve greater reduction in subgingival microbiota compared to conventional therapy.<sup>72</sup> Indeed, most bactericidal effects have been observed in laboratory studies and have little relevance to the protected environment of the periodontal biofilm.<sup>72</sup>

In addition, there is considerable conflict in clinical outcomes. Recent systematic reviews reported no greater clinical benefits from the application of dental lasers as mono-therapy or in combination with SRP as compared to conventional mechanical instrumentation.<sup>73,74</sup>

Photodynamic therapy is a minimally invasive procedure that attempts to kill bacteria via the chemical process of the oxidation. It relies on the combination of three components: a nontoxic photosensitizer agent such as an organic dye or a similar compound capable of absorbing light of a specific wavelength, a visible light (usually a low wavelength diode laser) and the molecular oxygen which is converted to reactive oxygen species primarily superoxide or singlet oxygen.<sup>75</sup> The cytotoxic product cannot migrate more than 0.02 mm after its formation, thus making it ideal for local application of the photodynamic therapy without endangering distant biomolecules, cells and organs.<sup>76</sup>

This technology has some limitations. It does not have any capability to mechanically remove plaque and calculus and it may not kill more than one-third of the bacteria in oral biofilms.<sup>77</sup> Thus, it may not substantially suppress pathogenic bacteria in periodontal pockets.<sup>78</sup>

Standard air-polishing devices are based on the air spray of sodium bicarbonate for supragingival polishing and stain removal. They cannot be used for subgingival instrumentation because of their high abrasiveness.<sup>79</sup> Recently, indications for the use of the air polishing technology have been expanded from supra- to subgingival use by the development of a new low-abrasive amino acid glycine-based powder delivered with a low-pressure device.<sup>80</sup> It is effective in removing the subgingival biofilm minimizing trauma to hard and soft tissues and it is perceived as more comfortable than hand and power-driven instrumentation.<sup>80</sup>

Current evidence of the efficacy of the glycine powder air spray derived from studies that enrolled patients in supportive maintenance therapy.<sup>80</sup> They reported no significant differences in either clinical or microbiological parameters compared to conventional hand and/or ultrasonic instrumentation in the short-term period.<sup>81,82</sup>

It is important to point out that the glycine polishing does not remove mineralized microbial deposits.<sup>82</sup> Thus, its application alone in the initial non-surgical treatment of periodontitis patients is questionable. In addition, the clinical outcome of air polishing versus other types of antimicrobial agents has yet to be determined.

In conclusion, the use of new technologies for the nonsurgical treatment of periodontal diseases needs to be evaluated in well designed and adequately powered studies and the overall quality of the body of evidence is still insufficient to support evidence-based decision-making.

## Conclusions

A sequence of interrelated steps is inherent to effective periodontal treatment: accurate diagnosis, comprehensive treatment, and periodontal maintenance. The primary goal of the periodontal therapy is to decrease the levels of pathogenic bacteria and, thus, to reduce the potential for progressive inflammation and recurrence of disease. Through scaling and root planing is still considered the gold standard in periodontal therapy. On the basis of the diagnosis, the medical history, the needs and expectations of the patient, and the final endpoints of the treatment

the clinician must select the operative protocol and devices more suitable for assuring periodontal health and long-term teeth survival.

Although professional dental care is of great importance for achieving such therapeutic goals, proper daily plaque control and patient compliance are essential part of successful periodontal therapy.

## Acknowledgements

The author thanks Dr Federica Romano, University Researcher at the Section of Periodontology Department of Surgical Sciences University of Torino, for drafting the article.

## References

1. American Academy of Periodontology. Position paper. Guidelines for periodontal therapy. *J Periodontol* 2001;72:1624–1628.
2. Nishihara T, Koseki T. Microbial etiology of periodontitis. *Periodontol 2000* 2004;36:14–26.
3. Page RC, Kornman KS. The pathogenesis of human periodontitis: an introduction. *Periodontol 2000* 1997;14:9–11.
4. Sanz M, Quirynen M. European Workshop in Periodontology Group A. Advances in the etiology of periodontitis. Consensus report of the 5th European Workshop in Periodontology. *J Clin Periodontol* 2005;32(Suppl 6):54–56.
5. Nunn ME. Understanding the etiology of periodontitis: an overview of periodontal risk factors. *Periodontol 2000* 2003;32:11–23.
6. Marsh PD. Dental plaque as a microbial biofilm. *Caries Res* 2004; 38:204–221.
7. Stewart PS, Costerton JW. Antibiotic resistance of bacteria in biofilms. *Lancet* 2001;358:135–138.
8. Sanz M, Teughels W. Innovations in nonsurgical periodontal therapy: consensus report of the Sixth European Workshop on Periodontology. *J Clin Periodontol* 2008;35(Suppl 8):3–7.
9. Aimetti M, Romano F, Guzzi N, Carnevale G. Full-mouth disinfection and antimicrobial therapy in generalized aggressive periodontitis: a randomized placebo-controlled trial. *J Clin Periodontol* 2012;39:284–294.
10. Drisko CH. Nonsurgical periodontal therapy. *Periodontol 2000* 2001; 25:77–88.
11. Baker KA. The role of dental professionals and the patient in plaque control. *Periodontol* 2000;1995;8:108–113.
12. Hujoel PP, Cunha-Cruz J, Loesche WJ, Robertson PB. Personal oral hygiene and chronic periodontitis: a systematic review. *Periodontol 2000*;2005;37:29–34.
13. Claydon NC. Current concepts in toothbrushing and interdental cleaning. *Periodontol 2000* 2008;48:10–22.
14. Ryan ME. Nonsurgical approaches for treatment of periodontal diseases. *Dent Clin N Am* 2005;49:611–636.
15. van der Weijden GA, Timmerman MF. A systematic review on the clinical efficacy of subgingival debridement in the treatment of chronic periodontitis. *J Clin Periodontol* 2002;29(Suppl 3):55–71.
16. Hallmon WW, Rees TD. Local anti-infective therapy: mechanical and physical approaches. A systematic review. *Ann Periodontol* 2003;8:99–114.
17. Adriaens PA, Adriaens LM. Effects of nonsurgical periodontal therapy on hard and soft tissues. *Periodontol 2000* 2004;36:121–145.
18. Suvan JE. Effectiveness of mechanical/nonsurgical

- pocket therapy. *Periodontol* 2000 2005;37:48–71.
19. Brunsvold MA, Zammitt KW, Dongari AL. Spontaneous correction of pathologic migration following periodontal therapy. *Int J Periodontics Restorative Dent* 1997;17:183–190.
  20. Sigh J, Deshpande RN. Pathologic migration spontaneous correction following periodontal therapy. *Quintessence Int* 2002;33:65–68.
  21. Cobb CM. Nonsurgical pocket therapy: Mechanical. *Ann Periodontol* 1996;1:443–490.
  22. Badersten A, Nilveus R, Egelberg J. Effect of nonsurgical periodontal therapy. I: moderately advanced periodontitis. *J Clin Periodontol* 1981;8:57–72.
  23. Greenstein G. Nonsurgical periodontal therapy in 2000: a literature review. *J Am Dent Assoc* 2000;131:1580–1592.
  24. Tunkel J, Heinecke A, Fleming T. A systematic review of efficacy of machine-driven and manual subgingival debridement in the treatment of chronic periodontitis. *J Clin Periodontol* 2002;29(Suppl 3):72–81.
  25. Hinrichs J, Somerman MJ, Iacono V, Genco RJ. Research, Science and Therapy Committee of the American Academy of Periodontology. Position paper: sonic and ultrasonic scalers in periodontics. *J Periodontol* 2000;71:1792–1801.
  26. Bower RC. Furcation morphology relative to periodontal treatment. Furcation entrance architecture. *J Periodontol* 1979;50:23–27.
  27. dos Santos KM, Pinto SC, Pochapski MT, Wambier DS, Pilatti GL, Santos FA. Molar furcation entrance and its relation to the width of curette blades used in periodontal mechanical therapy. *Int J Dent Hyg* 2009;7:263–269.
  28. Darby IB, Hodge PJ, Riggio MP, Kinane DF. Clinical and microbiological effect of scaling and root planing in smoker and non-smoker chronic and aggressive periodontitis patients. *J Clin Periodontol* 2005;32:200–206.
  29. Sanz I, Alonso B, Carasol M, Herrera D, Sanz M. Nonsurgical periodontal therapy. *J Evid Base Dent Pract* 2012;S1:76–88.
  30. Rabbani GM, Ash MM Jr, Caffesse RG. The effectiveness of subgingival scaling and root planing in calculus removal. *J Periodontol* 1981;52:119–123.
  31. Gellin RG, Miller MC, Javed T, Engler WO, Mishkin DJ. The effectiveness of the Titan-S sonic scaler versus curettes in the removal of subgingival calculus. A human surgical evaluation. *J Periodontol* 1986;57:672–680.
  32. Walmsley AD, Lea SC, Landini G, Moses AJ. Advances in power driven pocket/root instrumentation. *J Clin Periodontol* 2008;35(Suppl 8):22–28.
  33. Oda S, Nitta H, Setoguchi T, Izumi Y, Ishikawa I. Current concepts and advances in manual and power-driven instrumentation. *Periodontol* 2000 2004;36:45–58.
  34. Matuliene G, Pjetursson BE, Salvi GE, Schmidlin K, Bragger U, Zwhlen M, Lang NP. Influence of residual pockets on progression of periodontitis and tooth loss: results after 11 years of maintenance. *J Clin Periodontol* 2008;35:685–695.
  35. Deas DE, Mealey BL. Response of chronic and aggressive periodontitis to treatment. *Periodontol* 2000 2010;53:154–166.
  36. Danser MM, Timmerman MF, van Winkelhoff AJ, van der Velden U. The effect of periodontal treatment on periodontal bacteria on the oral mucous membranes. *J Periodontol* 1996;67:478–485.
  37. Koshy G, Corbet EF, Ishikawa I. A full-mouth disinfection approach tononsurgical periodontal therapy—Prevention of reinfection from bacterial reservoirs. *Periodontol* 2000 2004;36:166–178.
  38. Quirynen M, Bollen CM, Vandekerckhove BN, Dekeyser C, Papaioannou W, Eyssen H. Full- vs. partial mouth disinfection in the treatment of periodontal infections: Short-term clinical and microbiological observations. *J Dent Res* 1995;74:1459–1467.
  39. Bollen CM, Mongardini C, Papaioannou W, Van Steenberghe D, Quirynen M. The effect of a one-stage full-mouth disinfection on different intra-oral niches. Clinical and microbiological observations. *J Clin Periodontol* 1998;25:56–66.
  40. Quirynen M, Mongardini C, de Soete M, Pauwels M, Coucke W, van Eldere J, van Steenberghe D. The role of chlorhexidine in the one-stage full-mouth disinfection treatment of patients with advanced adult periodontitis. Long-term clinical and microbiological observations. *J Clin Periodontol* 2000;27:578–589.
  41. Quirynen M, De Soete M, Boschmans G, Pauwels M, Coucke W, Teughels W. Benefit of “one-stage full-mouth disinfection” is explained by disinfection and root planing within 24 hours: a randomized controlled trial. *J Clin Periodontol* 2006;33:639–647.
  42. Wennström JL, Tomasi C, Bertelle A, Dellasega E. Full-mouth ultrasonic debridement versus quadrant scaling and root planing as an initial approach in the treatment of chronic periodontitis. *J Clin Periodontol* 2005;32:851–859.

43. Jervøe-Storm PM, Semaan E, Al Ahdab H, Engel S, Fimmers R, Jepsen S. Clinical outcomes of quadrant root planing versus full-mouth root planing. *J Clin Periodontol* 2006;33:209–215.
44. Swierkot K, Nonnenmacher CI, Mutters R, Flores-de-Jacoby L, Mengel R. One-stage full-mouth disinfection versus quadrant and full-mouth root planning. *J Clin Periodontol* 2009;36:240–249.
45. Eberhard J, Jervøe-Storm PM, Needleman I, Worthington H, Jepsen S. Full-mouth treatment concepts for chronic periodontitis: a systematic review. *J Clin Periodontol* 2008; 35:591–604.
46. Lang NP, Tan WC, Krähenmann MA, Zwahlen M. A systematic review of the effects of full-mouth debridement with and without antiseptics in patients with chronic periodontitis. *J Clin Periodontol* 2008;35:8–21.
47. Aimetti M, Romano F, Guzzi N, Carnevale G. One-stage full-mouth disinfection as a treatment approach for generalized aggressive periodontitis. *J Periodontol* 2011;82:845–853.
48. Axelsson P, Lindhe J. Effect of controlled oral hygiene procedures on caries and periodontal disease in adults. Results after six years. *J Clin Periodontol* 1981;8:239–248.
49. Beikler T, Abdeen G, Schnitzer S, Salzer S, Ehmke B, Heinecke A, Flemmig TF. Microbiological shifts in intra- and extraoral habitats following mechanical periodontal therapy. *J Clin Periodontol* 2004;31:777–783.
50. Aimetti M, Romano F, Debernardi C. Effectiveness of periodontal therapy on the severity of cyclosporine A-induced gingival overgrowth. *J Clin Periodontol* 2005;32:846–850.
51. Aimetti M, Romano F, Peccolo D, Debernardi C. Nonsurgical periodontal therapy of gingival recession defects: evaluation of the restorative capacity of marginal gingiva. *J Periodontol* 2005;76:256–261.
52. Harris RJ. Creeping attachment associated with the connective tissue with partial-thickness double pedicle graft. *J Periodontol* 1997;68:890–899.
53. Shapiro A. Regeneration of interdental papillae using periodontal curettage. *Int J Periodontics Rest Dent* 1985;5:26–33.
54. Cortellini P, Tonetti M. Focus on intrabony defects: guided tissue regeneration. *Periodontol* 2000;22:104–132.
55. Carnevale G. Fiber retention osseous resective surgery: a novel conservative approach for pocket elimination. *J Clin Periodontol* 2007;34:182–187.
56. Tribble GD, Lamont RJ. Bacterial invasion of epithelial cells and spreading in periodontal tissue. *Periodontol* 2000;22:68–83.
57. Slots J, Ting M. *Actinobacillus actinomycetemcomitans* and *Porphyromonas gingivalis* in human periodontal disease: occurrence and treatment. *Periodontol* 2000;20:82–121.
58. Herrera D, Sanz M, Jepsen S, Needleman I, Roldan S. A systematic review on the effect of systemic antimicrobials as an adjunct to scaling and root planing in periodontitis patients. *J Clin Periodontol* 2002;29(Suppl 3):136–159.
59. Haffajee AD, Socransky SS, Gunsolley JC. Systemic anti-infective periodontal therapy. A systematic review. *Ann Periodontol* 2003;8:115–181.
60. Herrera D, Alonso B, Leon R, Roldan S, Sanz M. Antimicrobial therapy in periodontitis: the use of systemic antimicrobials against the subgingival biofilm. *J Clin Periodontol* 2008;35(Suppl 8):45–66.
61. Herrera D, Matesanz P, Bascones-Martinez A, Sanz M. Local and systemic antimicrobial therapy in periodontics. *J Evid Base Dent Pract* 2012;81:60–80.
62. Marsh PD. Dental plaque: biological significance of a biofilm and community life-style. *J Clin Periodontol* 2005;32(Suppl 6):7–15.
63. Larsen T. Susceptibility of *Porphyromonas gingivalis* in biofilms to amoxicillin, doxycycline and metronidazole. *Oral Microbiol Immunol* 2002;17:267–271.
64. Krayner GW, Leite RS, Kirkwood KL. Nonsurgical chemotherapeutic treatment strategies for the management of periodontal diseases. *Dent Clin N Am* 2010;54:13–33.
65. Mombelli A, Cionca N, Almaghlouth A, Décaillet F, Curvoisier DF, Giannopoulos C. Are there specific benefits of amoxicillin plus metronidazole in Aggregatibacter actinomycetemcomitans-associated periodontitis? A double masked, randomized clinical trial of efficacy and safety. *J Periodontol* 2013;84:715–724.
66. Meissner G, Kocher T. Calculus detection technologies and their clinical application. *Periodontol* 2000;2011;55:189–204.
67. Aoki A, Sasaki KM, Watanabe H, Ishikawa I. Lasers in nonsurgical periodontal therapy. *Periodontol* 2000;2004;36:59–97.
68. Cobb CM, Low SB, Coluzzi DJ. Lasers and the treatment of chronic periodontitis. *Dent Clin N Am* 2010;54:35–53.
69. Schwarz F, Aoki A, Sculean A, Becker J. The impact of laser application on periodontal and peri-implant



- wound healing. *Periodontol 2000* 2009;51:79–108.
70. Israel M, Cobb CM, Rossmann JA, Spencer P. The effects of CO<sub>2</sub>, Nd:YAG and Er:YAG lasers with and without surface coolant on tooth root surfaces. An in vitro study. *J Clin Periodontol* 1997;24:595–602.
  71. Herrero A, Garcia-Kass AI, Gomez C, Sanz M, Garcia-Nunez JA. Effect of two kinds of Er:YAG laser systems on root surface in comparison to ultrasonic scaling: an in vitro study. *Photomed Laser Surg* 2010;28:497–504.
  72. Cobb CM. Lasers in periodontics: a review of the literature. *J Periodontol* 2006;77:545–564.
  73. Karlsson MR, Diogo Lofgren CI, Jansson HM. The effect of laser therapy as an adjunct to non-surgical periodontal treatment in subjects with chronic periodontitis: a systematic review. *J Periodontol* 2008;79:2021–2028.
  74. Schwarz F, Aoki A, Becker J, Sculean A. Laser application in nonsurgical periodontal therapy: a systematic review. *J Clin Periodontol* 2008;35(8 Suppl):29–44.
  75. Sharman WM, Allen CM, van Lier JE. Photodynamic therapeutics: basic principles and clinical applications. *Drug Discov Today* 1999;4:507–517.
  76. Moan J, Berg K. The photodegradation of porphyrins in cells that can be used to estimate the lifetime of singlet oxygen. *Photochem Photobiol* 1991;53:549–553.
  77. Fontana CR, Abernethy AD, Som S, Ruggiero K, Doucette S, Marcantonio RC, Boussios CI, Kent R, Goodson JM, Tanner AC, Soukos NS. The antibacterial effect of photodynamic therapy in dental plaque-derived biofilms. *J Periodontol Res* 2009; 44:751–759.
  78. Novaes AB Jr, Schwartz-Filho HO, de Oliveira RR, Feres M, Sato S, Figueiredo LC. Antimicrobial photodynamic therapy in the nonsurgical treatment of aggressive periodontitis: microbiological profile. *Lasers Med Sci* 2012;27:389–395.
  79. Kontturi-Narhi V, Markkanen S, Markkanen H. Effects of air-polishing on dental plaque removal and hard tissues as evaluated by scanning electron microscopy. *J Periodontol* 1990;61:334–338.
  80. Petersilka GJ. Subgingival air-polishing in the treatment of periodontal biofilm infection. *Periodontol 2000* 2011;55:124–142.
  81. Wennström JL, Dahlen G, Ramberg P. Subgingival debridement of periodontal pockets by air polishing in comparison with ultrasonic instrumentation during maintenance therapy. *J Clin Periodontol* 2011;38:820–827.
  82. Sculean A, Bastendorf KD, Becker C, Bush B, Einwag J, Lanoway C, et al. A paradigm shift in mechanical biofilm management? Subgingival air-polishing: a new way to improve mechanical biofilm management in the dental practice. *Quintessence Int* 2013;44:475–477.